

# Metastatic spinal lymphoma: A case report

Rizaldy Taslim Pinzon<sup>1,2</sup>, Patrick Kurniawan Latumahina<sup>1</sup>

<sup>1</sup>School of Medicine, Duta Wacana Christian University, Yogyakarta, Indonesia

<sup>2</sup>Department of Neurology, Bethesda Hospital, Yogyakarta, Indonesia

## ABSTRACT

**Background.** Metastatic spinal lymphoma is a rare case, especially with the initial clinical manifestation of back pain, which only occurs in less than 5% of patients. We report a case of an adult male with low back pain that was found to be metastatic spinal lymphoma, and this study is the first to report a case of metastatic spinal lymphoma with initial complaints of back pain.

**Case presentation.** A 66-year-old male presented with progressive lower extremity weakness since 2 weeks. The initial complaint was back pain since 2 months before admission. The patient had no history of previous trauma, history of hypertension, diabetes, or heart disease was also denied. The patient admitted that there was a weight loss in the last 2-3 months. Radiologic examination of the lumbar spinal MRI (magnetic resonance imaging) without contrast was performed and showed an impression of bone metastasis at the corpus VL (lumbar vertebrae) 1-5, and paraspinal muscle spasm.

**Conclusion.** We report rare case of metastatic spinal lymphoma, spinal lymphoma should be considered and monitored for non-specific clinical findings that resemble other possible causes.

**Keywords:** low back pain, non-Hodgkin's lymphoma, metastasis, spine, paraparesis

## BACKGROUND

Non-Hodgkin's lymphoma (NHL) can occur in all segments of the CNS (central nervous system), from the brain parenchyma to the peripheral nerves. The effects of this malignancy may include radiculopathy or compression of the associated nerves. NHL in the CNS can be primary disease or secondary to metastasis from surrounding organs [1].

Back pain as first manifestation of metastatic lymphoma is rare, occurring in less than 5% of patients [1]. Although NHL metastasis to the spine is rare as an initial manifestation of malignancy, it should be considered in cases of spinal cord compression thought to be due to malignant disease [2]. The aim of this case report is to describe the presentation and diagnostic imaging of a patient with symptoms of LBP and metastatic lymphoma.

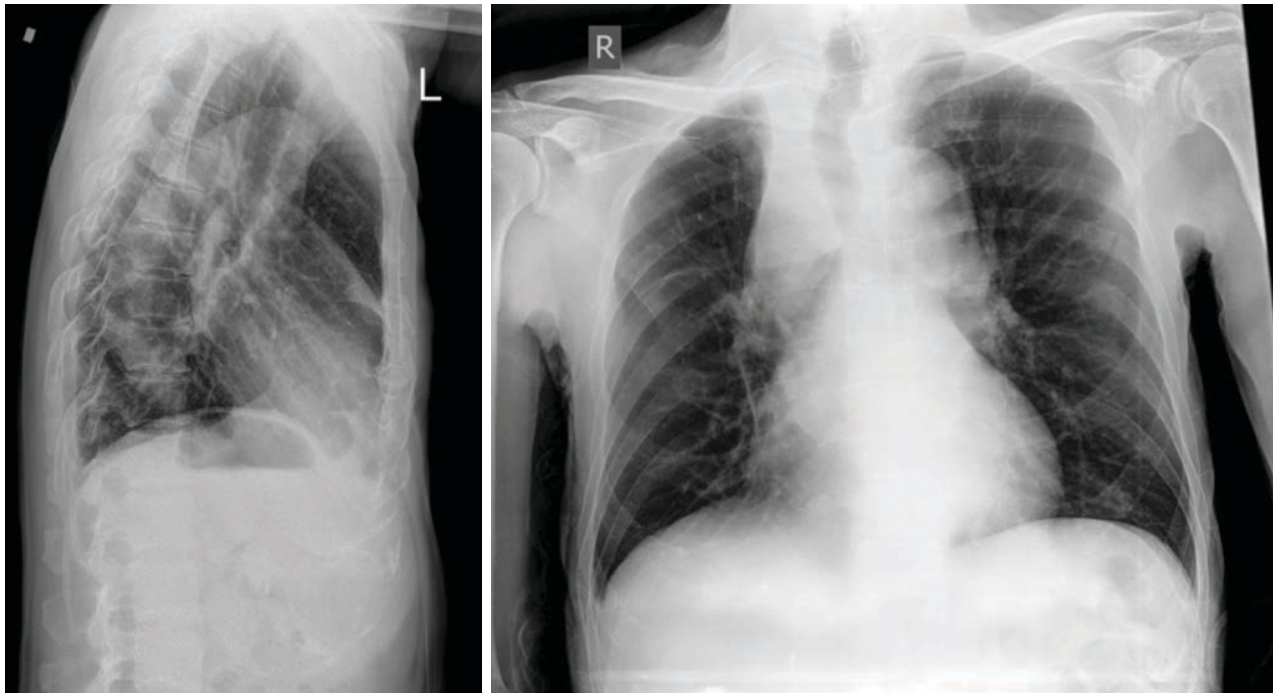
## CASE PRESENTATION

A 66-year-old male admitted to our hospital with complaints of weakness in both legs that was felt

since 2 weeks ago. The weakness was felt progressively during these 2 weeks and worsened until one day before admission to the hospital. The patient was difficult to walk due to weakness in his legs. There was no pain in both limbs. The complaint began with low back pain for 2 months with pain at the level of the navel. The pain is felt intermittent and does not spread to other areas, the pain is felt like being stabbed. Pain is aggravated by walking, sitting-standing activities and improves with rest. The pain is more severe in the afternoon and evening. Pain scale with VAS (Visual analogue scale) 6. Complaints of tingling, burning, electric shock are denied. There were no complaints of micturition or defecation. The patient had no history of previous trauma, history of hypertension, diabetes, or heart disease was also denied. The patient admitted that there was a weight loss in the last 2-3 months by 7 kg, from 61 kg to 54 kg without a definite cause. Weight loss was accompanied by a decrease in the patient's appetite. The patient has a history of GERD (gastroesophageal reflux disease) and has consulted

*Corresponding authors:*  
Rizaldy Taslim Pinzon  
E-mails: drpinzon17@gmail.com

*Article History:*  
Received: 14 June 2023  
Accepted: 30 June 2023



**FIGURE 1.** X-ray thorax lateral view showing a firm mediastinal mass

an internist with routine consumption of lansoprazole and sucralfate.

At the time of admission, the patient's was fully conscious. The patient's body temperature was 37.4°C, blood pressure 115/67 mmHg, pulse rate 121x/min, respiratory rate 18x/min, and oxygen saturation 97%. The neurological examination revealed weakness in both limbs. The other neurological examination showed no abnormality. The patient admitted that her family had no similar complaints, no history of diabetes, hypertension, or heart disease. However, the patient had an older sister who had died with a history of breast cancer 10 years ago. The patient herself was a smoker from the age of 28 until the age of 31.

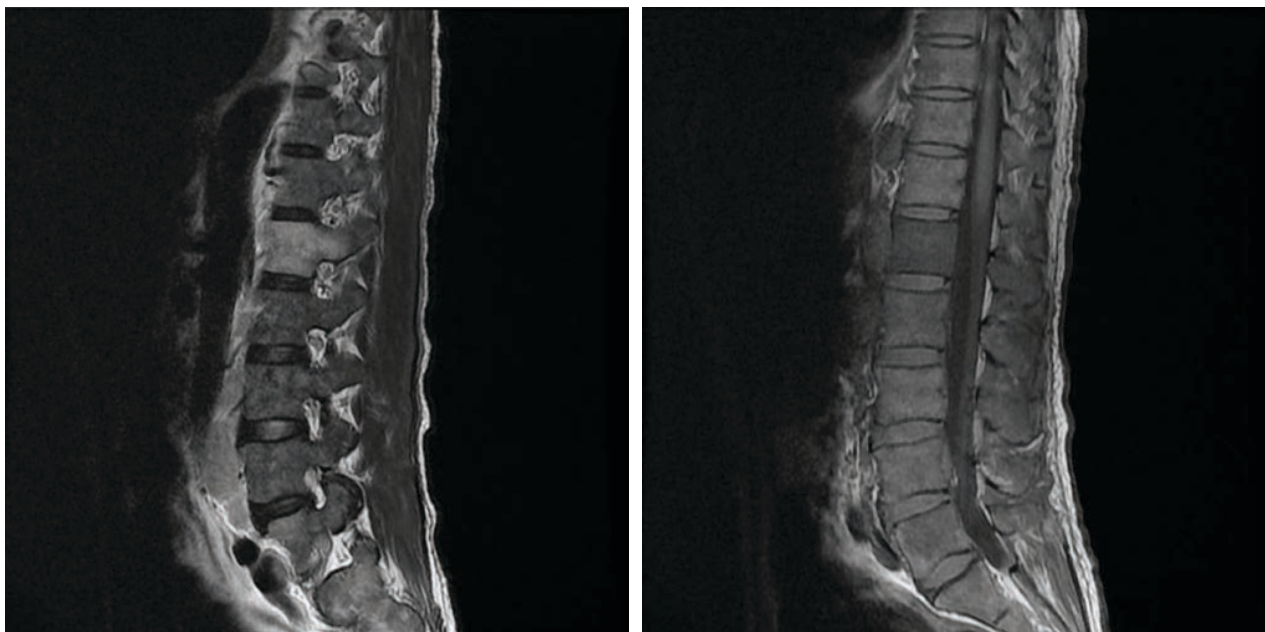
Laboratory examination showed normochromic anemia, neutrophilia, monocytosis, and lymphopenia. The patient's hematocrit and erythrocyte counts were low, as were the patient's total protein and albumin. Electrolyte examination revealed hyponatremia and hypokalemia. X-ray examination of the thorax was performed and a mass was found in the mediastinum (Figure 1). Pharmacological therapy was given to the patient, which included methylprednisolone (125mg), pantoprazole (40 mg), mecobalamin (500 mcg), anemolate (1 mg), domperidone (10 mg), gabapentin (100 mg) and PRC (packed red cell) transfusion of 1 colf. On daily follow-up, the patient's clinical condition was found to be improving.

Follow-up examinations were performed on the patient to find the etiology of the patient's disease. The results of tumor marker examinations such as CEA (carcinoemnyronic antigen) and PSA (prostate specific antigen) showed normal results. The results

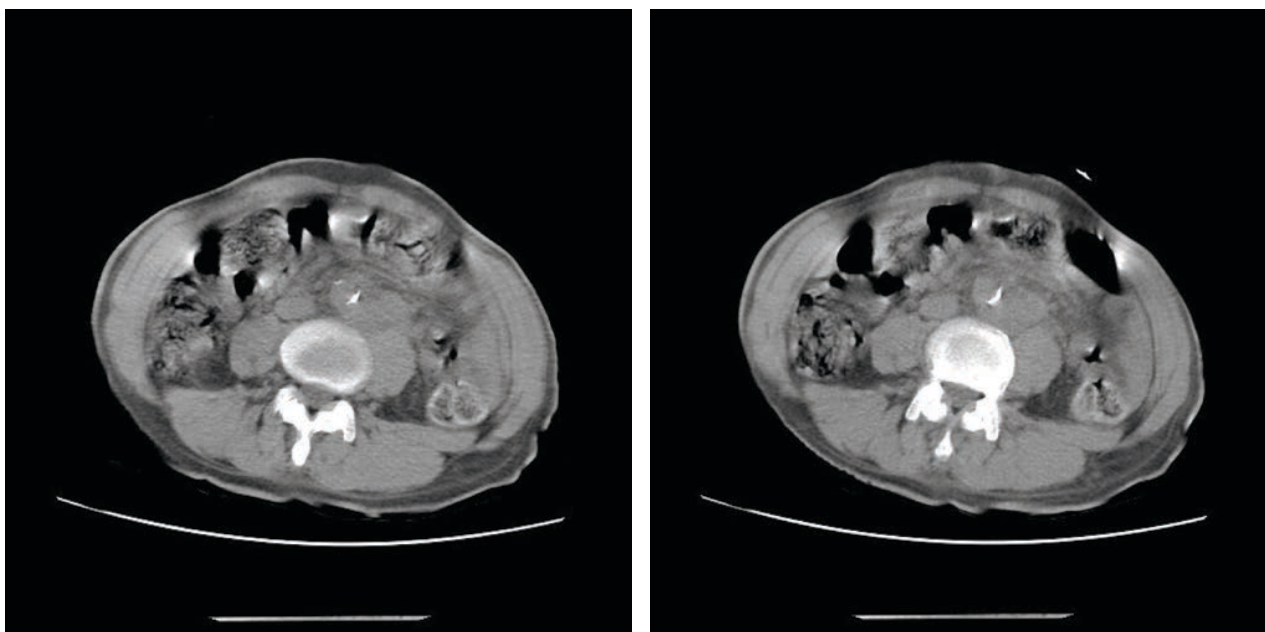
of peripheral blood cytology also showed only normocytic normochromic anemia. Radiologic examination of the lumbar spinal MRI (magnetic resonance imaging) without contrast was performed and showed an impression of bone metastasis at the corpus VL (lumbar vertebrae) 1-5, and paraspinal musculospasm (Figure 2). MSCT (multi-sliced computed tomography) of the abdomen was performed with multiple lymphadenopathy along the abdominal paraaorta suggestive of lymphoma accompanied by hepatic nodules suspected of hepatal metastasis (Figure 3). Exploratory laparotomy and lymphonodi biopsy were performed on the patient with the result of lymphoma with mixed cellularity. After 16 days of treatment, the patient was discharged and a chemotherapy regimen was planned for the patient.

## DISCUSSION

Low back pain as an early manifestation of lymphoma is rare, occurring in only 5% of patients [1]. The rarity of this case is also evidenced by the scarcity of existing literature where there are only a few case reports and case series that describe spinal lymphoma and the prevalence is difficult to estimate [3]. To the best of our knowledge there are no case reports in Indonesia describing spinal lymphoma metastasis. Clinically most patients will present with complaints of back pain and functional decline of both lower extremities, spasticity, and urinary dysfunction. There may also be systemic "B" symptoms such as fever without apparent cause, weight loss without apparent cause >10% of body weight within 6 months, and night sweats



**FIGURE 2.** Lumbar spinal MRI showed lumbosacral vertebrae bone structure with inhomogeneous intensity at VL1-5 with diffuse pathologic intensity spots at the corpus of VL1-5. The intervertebral disc showed homogeneous decreased intensity especially the VL4-5 segment with mild bulging disc but no significant herniation to the intraspinal



**FIGURE 3.** CT abdomen showed enlarged paraortic lymphonodi abdominalis with lobulated shape where post contrast application did not show significant enhancement

[4,5]. Our patient had prodromal symptoms of low back pain followed by progressive weakness of the lower limbs. Our patient also had systemic symptoms of weight loss but fever and night sweats were denied.

Risk factors for lymphoma are multifactorial, ranging from genetic disorders, infection, inflammation, a history of close relatives with lymphoma, immunosuppressed conditions, as well as modifiable factors such as a history of cigarette consumption, obesity, and breast implants [6]. Our patient did not have a history of immunosuppression or family history of lympho-

ma, but there were other factors such as the patient's sibling history of breast cancer. Our patient was also a smoker although the patient had quit smoking a long time ago. The suspicion of malignancy in this patient was due to the non-specific results of the neurological examination and the systemic symptoms that accompanied our patient. Subsequent radiologic examination also raised suspicion of metastasis to the spinal area. There is some literature that also links the incidence of lymphoma with infection from Epstein-Barr Virus related to immunodeficiency [1,7]. Spinal NHL



(non-Hodgkin's lymphoma) can occur at any age, but is most common in the fifth decade and above [8]. The spinal cord is the third most common location for metastatic spread after the lungs and liver. NHL affecting the CNS (central nervous system) mostly affects the brain parenchyma, meninges, spinal cord and epidural spatium. NHL that occurs in the intramedullary spinal cord is very rare, where most NHL occurs in the epidural primary or secondary [1,9].

Intramedullary spinal cord metastatic spread is hypothesized to occur from spread through arteries, from Batson's venous plexus, or may be invasion from leptomeningeal lymphoma [10]. There is also a hypothesis that spread can occur to the retroperitoneal lymphonodes through the intervertebral venous plexus [11]. In our patient, we found an enlarged picture of lymphonodi paraaorta abdominalis which makes consideration in the spread of lymphoma to the spinal cord. The definitive diagnosis of lymphoma currently uses a lymphonodi biopsy which can be done openly or with the help of CT guided biopsy [6,12,13]. In radiologic examination itself, the use of MRI is still the main choice to be able to determine the lesion picture clearly [3,14].

Chemotherapy pharmacology treatment was planned in our patient. Data shows inconsistent results on the management of spinal NHL due to the small number of cases. Some previous studies have shown that some chemotherapeutic agents can achieve full remission such as methotrexate, alkyl-

ating agents, or antimetabolites. Surgical procedures are still debated as there is still no evidence to suggest that surgery is more effective than existing intravenous pharmacology [5,15-17]

## CONCLUSION

We report rare case of metastatic spinal lymphoma, spinal lymphoma should be considered and monitored for non-specific clinical findings that resemble other possible causes.

### *Ethical Approval:*

This study requires no approval from the ethical committee due to the nature of this case report. However, this study has obtained permission from the Bethesda Hospital Research and Development Department. In accordance with the Declaration of Helsinki, the patient's identity was hidden

### *Consent for publication:*

Verbal informed consent has been obtained from the patient to publish this case report and any accompanying images.

### *Acknowledgements:*

We would like to express our gratitude for the contribution of the patient and the patient's family in this case report.

*Conflict of interest:* none declared

*Financial support:* none declared

## REFERENCES

- Roug IK, McCartney LB. Metastatic non-Hodgkin lymphoma presenting as low back pain and radiculopathy: a case report. *J Chiropr Med.* 2012 Sep;11(3):202-6. doi: 10.1016/j.jcm.2012.05.008. PMID: 23449990; PMCID: PMC3437349.
- Luo CC. Spinal cord compression secondary to metastatic non-Hodgkin's lymphoma: a case report. *Arch Phys Med Rehabil.* 2005 Feb;86(2):332-4. doi: 10.1016/j.apmr.2004.06.063. PMID: 15706563.
- Zakaria Mohamad Z, Kow RY, Low CL, Hamdan AH, Awang MS. Primary B-cell Lymphoma of the Thoracic Spine: A Rare Cause of Spinal Cord Compression. *Cureus.* 2021 Jul 24;13(7):e16608. doi: 10.7759/cureus.16608. PMID: 34447645; PMCID: PMC8381466.
- Zheng JS, Wang M, Wan S, Zhou YQ, Yan M, Chen QF, Zhan RY. Isolated primary non-Hodgkin's lymphoma of the thoracic spine: a case report with a review of the literature. *J Int Med Res.* 2010 Jul-Aug;38(4):1553-60. doi: 10.1177/147323001003800440.
- D'cruz J, Adeeb N, Von Burton G, Georgescu M-M, Larmeu L et al. Diagnosis and management of intramedullary spinal cord lymphoma: A case illustration and review of literature. *Interdis Neurosurg.* 2020; 19:100552.
- Lewis WD, Lilly S, Jones KL. Lymphoma: Diagnosis and Treatment. *Am Fam Physician.* 2020 Jan 1;101(1):34-41. PMID: 31894937.
- Boffetta P, de Vocht F. Occupation and the risk of non-Hodgkin lymphoma. *Cancer Epidemiol Biomarkers Prev.* 2007 Mar;16(3):369-72. doi: 10.1158/1055-9965.EPI-06-1055. PMID: 17372232.
- Hashi S, Goodwin CR, Ahmed AK, Sciubba DM. Management of extramedullary lymphoma of the spine: a study of 30 patients. *CNS Oncol.* 2018 Apr;7(2):CNS11. doi: 10.2217/cns-2017-0033. Epub 2018 Apr 30. PMID: 29706086; PMCID: PMC5977280.
- Hatrick NC, Lucas JD, Timothy AR, Smith MA. The surgical treatment of metastatic disease of the spine. *Radiother Oncol.* 2000 Sep;56(3):335-9. doi: 10.1016/s0167-8140(00)00199-7.
- Flanagan EP, O'Neill BP, Habermann TM, Porter AB, Keegan BM. Secondary intramedullary spinal cord non-Hodgkin's lymphoma. *J Neurooncol.* 2012 May;107(3):575-80. doi: 10.1007/s11060-011-0781-4. Epub 2011 Dec 22. PMID: 22189600.
- Levitt LJ, Dawson DM, Rosenthal DS, Moloney WC. CNS involvement in the non-Hodgkin's lymphomas. *Cancer.* 1980 Feb;45(3):545-52. doi: 10.1002/1097-0142(19800201)45:3<545::aid-cnrcr2820450322>3.0.co;2-6. PMID: 6986199.
- Ansell SM. Hodgkin Lymphoma: Diagnosis and Treatment. *Mayo Clin Proc.* 2015 Nov;90(11):1574-83. doi: 10.1016/j.mayocp.2015.07.005. PMID: 26541251.
- Gaddey HL, Riegel AM. Unexplained Lymphadenopathy: Evaluation and Differential Diagnosis. *Am Fam Physician.* 2016 Dec 1;94(11):896-903. PMID: 27929264.
- Pokhrel NB, Prasad R, Paudel S, Kafle D, Pokharel RK. Primary spinal epidural non-Hodgkin's diffuse large B-cell lymphoma: A case report. *Clin Case Rep.* 2020 Sep 21;8(11):2276-2280. doi: 10.1002/ccr3.3122. PMID: 33235776; PMCID: PMC7669400.
- Benz R, Viacelli A, Taverna C, Schelosky L. Paroxysmal non-kinesigenic dyskinesia due to spinal cord infiltration of low-grade B cell non-Hodgkin's lymphoma. *Ann Hematol.* 2012 Mar;91(3):463-5. doi: 10.1007/s00277-011-1258-4. Epub 2011 May 28. PMID: 21626000.
- Ezon IC, Barteselli G, Rosenberg J, Freeman WR. Concurrent primary vitreoretinal and spinal cord lymphoma: a unique entity. *JAMA Ophthalmol.* 2014 Jul;132(7):902-4. doi: 10.1001/jamaophthalmol.2014.419. PMID: 25010176.
- Guzik G. Primary B-cell Spinal Cord Lymphoma of the Cervical Spine. *Ortop Traumatol Rehabil.* 2018 Jun 30;20(3):219-227. doi: 10.5604/01.3001.0012.2131. PMID: 30152771.